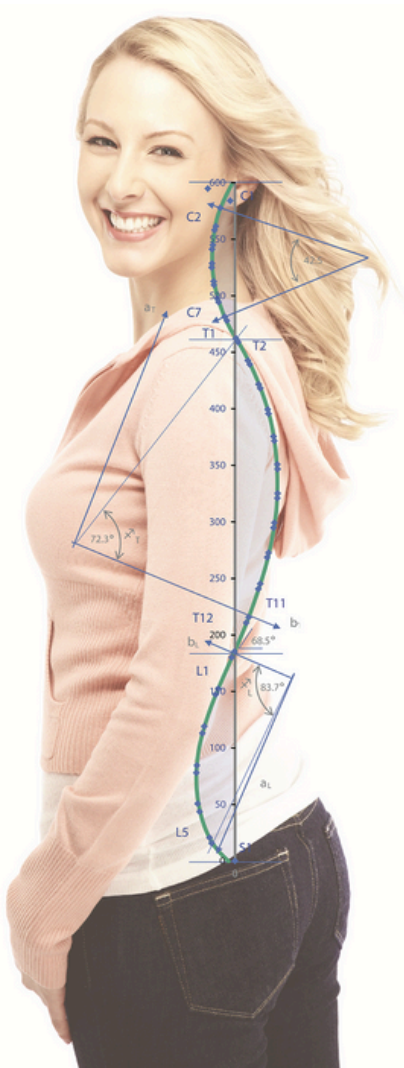




X-RAY Report of Findings



Prepared for : [REDACTED]

Evaluation Date : 8/26/2025

Date X-Ray Taken: 8/26/2025



Prepared by:
Circadian Chiropractic & Sport
5250 17th Street, Unit 101
Sarasota, Florida
34235

Welcome

You have chosen to be a patient at an office that utilizes posture and x-ray to evaluate your spinal alignment. While a postural analysis can provide a knowledge of gross postural/spinal abnormalities (your outside alignment), only a radiographic evaluation can provide the details of your spine's alignment and condition (your inside alignment). Your spinal alignment, any possible spinal arthritis, and disc disease (S.A.D.D.) are both conditions of interest to your doctor. With the knowledge from analyzing your spinal x-rays, your health care provider can determine a beginning clinical impression (diagnosis from any abnormalities found on your x-rays) and determine an initial program of corrective care.

What is Normal for the Spine?

Your doctor performs several levels of analyses on your spinal x-rays. First, an overall evaluation of your alignment in front-to-back radiographic views and your side radiographic views is performed. In the Front view, your spine should be straight or vertically aligned with gravity. In the Side view, your spine should have four natural curves. These four curves should be a convex forward curve in the neck (termed lordosis), a concave curve in the rib cage area (termed thoracic kyphosis), another convex forward curve in the low back (termed lumbar lordosis), and a concave curve in your sacrum-tailbone area. Figure 1 illustrates this alignment.

Figure 1.

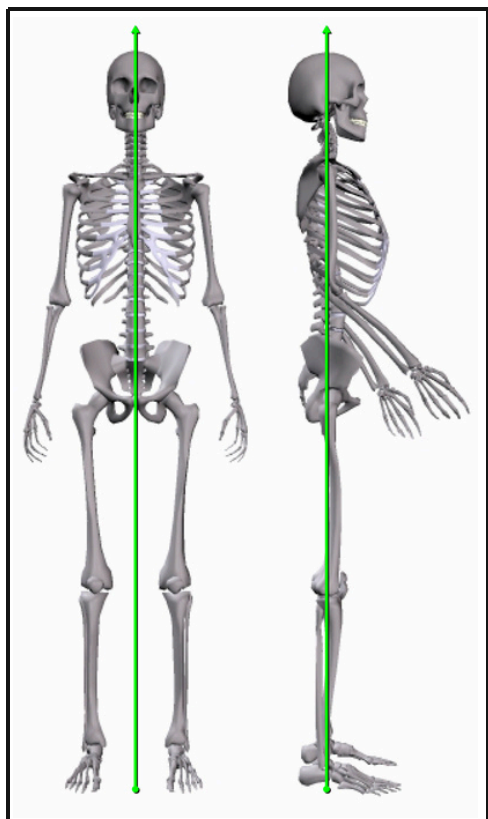


Figure 1.

Normal spinal alignment is depicted in both the front and Side views. In the front view, the center of mass of the skull, thorax, and pelvis are in a vertical line which falls between mid-stance. The spinal column is vertically aligned with respect to gravity. In the side view, the center of mass of the skull, thorax, and pelvis are in vertical alignment over the ankle. The cervical spine is lordotic, the thoracic spine is kyphotic, and the lumbar spine is lordotic.

X-RAY Report of Findings

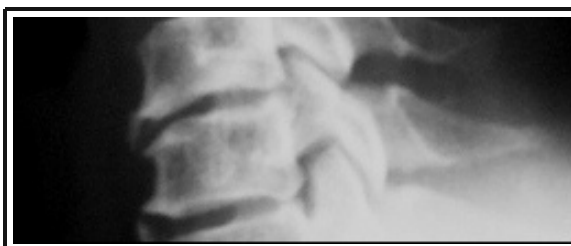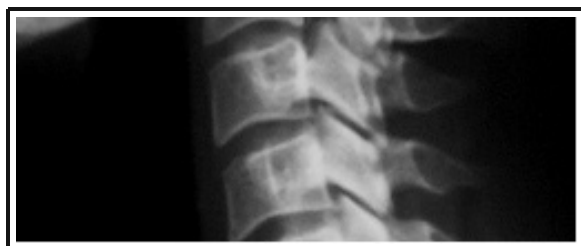Introduction

For a second evaluation, your doctor looks for any obvious spinal ligament damage by observing individual spinal vertebra for any left or right misalignments in the front view and any forward or backward misalignments in the side view. Figure 2 illustrates cases of spinal ligament damage.




Figure 2. Ligament damage is present when a spinal vertebra does not align properly with either the vertebra immediately above it or immediately below it. In the 1st and 2nd picture, abnormal alignment of a vertebra translating left and right, signifying spinal ligament damage, is illustrated for the front view. In the 3rd picture, in the side view, backward slippage of the top vertebra is depicted. In the 4th picture, in the side view, forward slippage is shown.

For a third evaluation of your spinal x-rays, your doctor checks each vertebra for normal contour and density. This evaluation determines the state of any possible spinal arthritis and disc disease (S.A.D.D.) that you may have. Figure 3 provides an example of this analysis.



For a fourth evaluation of your spinal x-rays, your doctor checks the spacing between each pair of vertebrae. This spacing is where the spinal discs lie. Any narrowing of the normal spacing indicates disc injury and disc disease. Figure 4 presents an example of disc narrowing and disease.

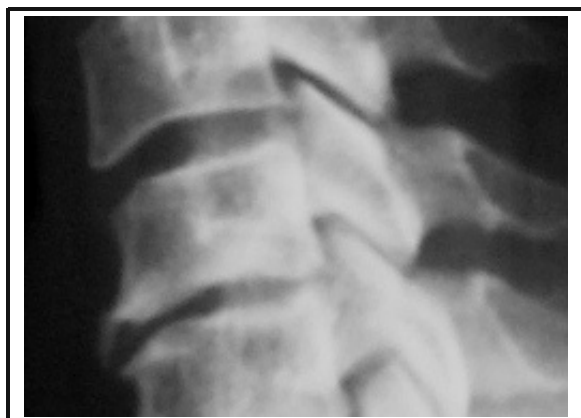

Figure 4. Between the top and middle vertebrae, a normal disc spacing is seen. However, between the middle and lower vertebrae, the disc space is narrowed. This indicates that the disc has been injured and is losing its water content. While disc disease can have several causes, generally, it is a result of abnormal stress (pressures) applied to the disc from abnormal spinal alignment.

X-RAY Report of Findings

Introduction

For a fifth evaluation of your spinal x-rays, your doctor determines the alignment of each spinal region (neck, rib cage, and low back) compared to the region immediately below by comparing each region to a vertical line in both the front view and side view. The following vertebrae should be vertically aligned with each other: C1 (first neck vertebra), T1 (first rib cage vertebra), T12 (last rib cage vertebra at the level of your kidneys), and S1 (first vertebra in your sacrum). Figure 5 illustrates this alignment for the three separate spinal regions, neck, rib cage, and low back.

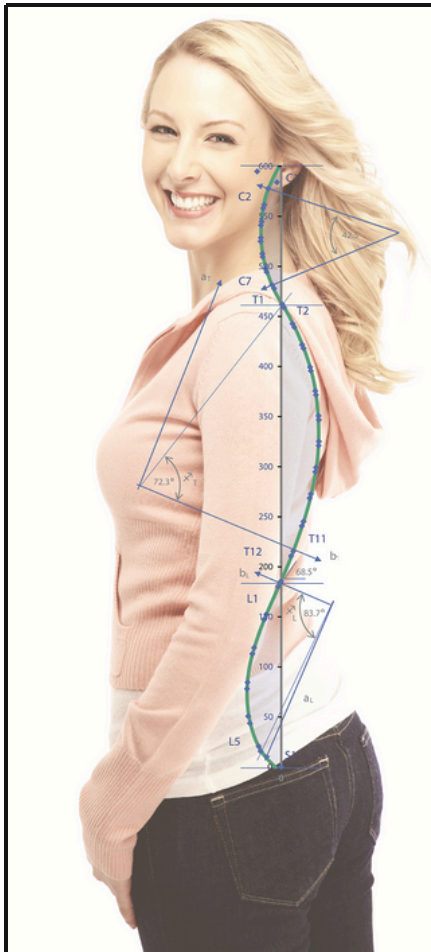


Figure 5.

Normal spinal balance from the side is when a vertical line will pass through C1, T1, T12, and S1. This can be observed all at once on a full-spine side view x-ray or for individual regions on smaller x-ray views, termed sectional x-rays. The figure to the left shows only the posterior points of each vertebra. If we look at the side view cervical (neck), C1 is aligned with T1 (thick vertical black line), with a forward convex curve termed cervical lordosis. If we just look at the side view of rib cage (thoracic), T1 is aligned with T12 and there is the presence of a concave curvature (termed thoracic kyphosis). If we look at the side view lumbar (low back), T12 is aligned with S1, with a forward convex curve termed lumbar lordosis.

For a sixth evaluation, your doctor measures any displacements of the individual spinal vertebra and/or spinal regions. These measurements are in degrees for any angular or turning (rotational) displacements and in millimeters for any sliding or shifting (translational) displacements. Figures 6 and 7 illustrate these measurements.

X-RAY Report of Findings

Introduction

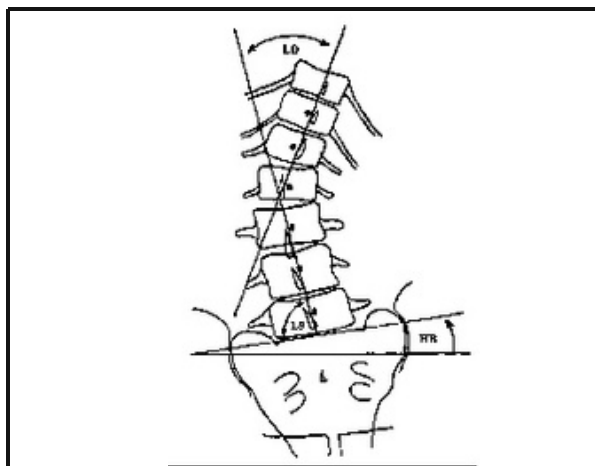
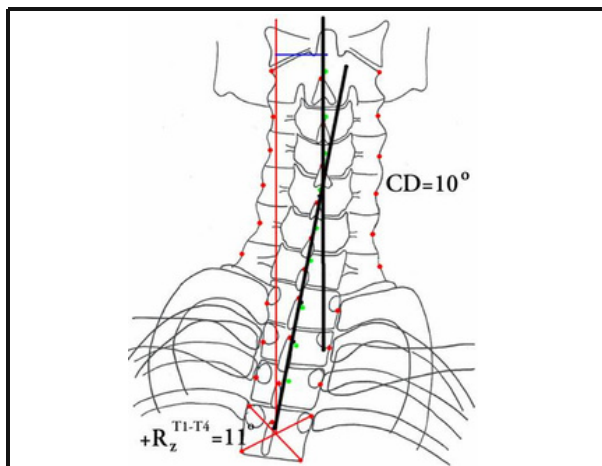


Figure 6. In the front x-ray views, lines are drawn through the centers of mass of each spinal vertebra to measure your abnormal spinal alignment. In A, an example of an analysis of abnormal spinal alignment of the neck in the front view is provided, and in B, an example of an analysis of abnormal spinal alignment of the low back is shown.

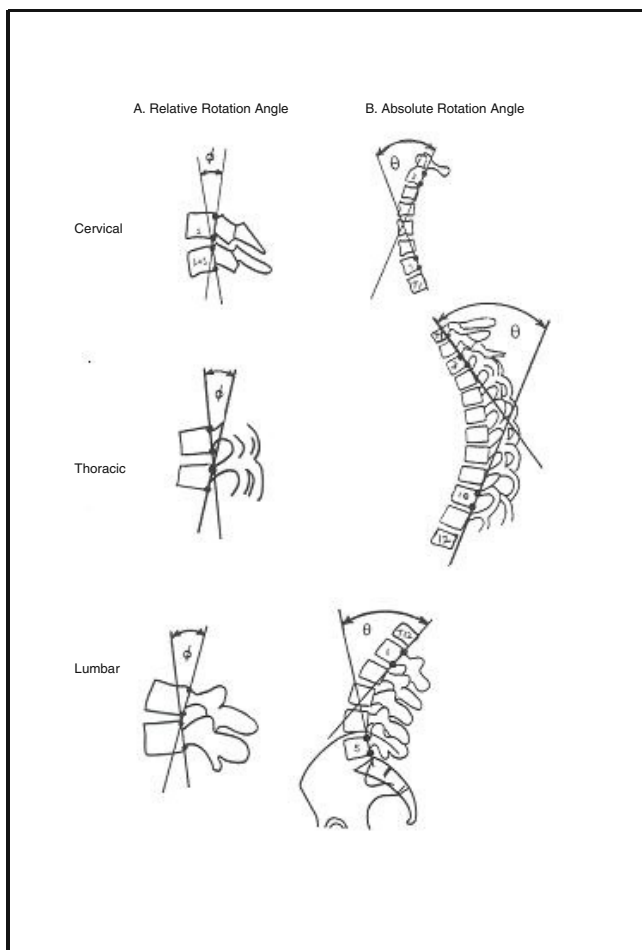


Figure 7. In the side view, lines are drawn on the back part of each spinal vertebra. These lines are termed “Posterior Tangents”. When measuring angles between adjacent posterior tangents, the angles are termed Relative Rotation Angles (RRA). When angles are formed by posterior tangents on the top and bottom vertebrae in any spinal region, these angles are termed Absolute Rotation Angles (ARA). There are precise normal values published in the scientific literature for each spinal RRA and each spinal ARA. Your alignment will be compared to these published normal values.



What Are the Risks of X-ray Exposure?

While we must constantly work towards the reduction of health risks in all endeavors, we may be led to accept a minimal level as normal. While there is no data indicating diagnostic radiology has a present risk, any radiation dose must be compared to the benefits of useful information gained. The necessity for appropriate treatment selection is indeed an acceptable trade-off when put into perspective. The need for x-ray imaging is especially clear when one considers that radiographic (x-ray) imaging is the only valid method for determining abnormal spinal alignment and the presence of any spinal degeneration. However, since 1990, there has been a growing knowledge base that suggests medical x-rays may have health benefits. While an actual benefit from radiation exposure may seem outrageous, there is much scientific evidence for this phenomenon. This phenomenon/field of study is termed Radiation Hormesis.

[12-27,29-48]

Radiation Hormesis is the stimulatory or beneficial effect of low doses of ionizing radiation. This topic is in direct conflict with the "Linear No-Threshold Hypothesis" (LNT), which has been assumed to be true for more than 50 years. This LNT model comes from estimating the risks at lower doses of radiation, in the absence of data, by extrapolating in a linear model from the extremely large doses of radiation from atomic bombs dropped on Japan in the 1940s.

This LNT model has been used to set limits of radiation exposure by all official and governmental associations around the world.[17] Recently in 2003, Kauffman[12] reiterated that authors critical of exposure from diagnostic radiation always use the LNT model. This use of the LNT model includes the recent 2005 report by the USA National Research Council.[28] This report stated, "there will be some risk, even at low doses (100 mSv or less), although the risk is small" and "there is no direct evidence of increased risk of non-cancer diseases at low doses." [28] This 2005 report ignored and contradicted an earlier 2003 review by Kant et al.[29]

For a comparison of exposures, USA citizens are exposed to an average annual natural background radiation level of 3 mSv, while exposure from a chest x-ray is approximately 0.1 mSv and exposure from a whole body computerized tomography (CT) scan is approximately 10 mSv.[28] Also it is noted that 10mSv = 1,000mrem, which equates to about 46 cervical series or 8 lumbar series. Thus, the x-ray views taken to evaluate your spine in this office constitute a very small exposure compared to a CT scan or even annual background radiation from your natural environment.

Thus, it is obvious that the extremely small health risks (and maybe even some health benefits), associated with the x-ray exposure, needed to determine the state of health of your spine in this Report, are small indeed compared to the knowledge gained from this information.

From your radiographic examination at our office, we have determined the state of degeneration of your spine, and have determined the exact displacements of your spine. This knowledge not only gives us a working Clinical Impression/diagnosis of your spinal condition, but also determines the type of treatment that is needed to improve your spinal health condition.

We hope that you appreciate our thoroughness in examining and diagnosing your spinal health problems. In the next few pages, for each x-ray view obtained, we will present a normal view on the left hand side to compare to your x-ray on the right hand side. A table of values of normal measurements and your abnormal alignment will be provided on a Summary page after the x-ray photographs.



X-RAY Report of Findings

This Analysis Has Been Researched

We are proud to state that the normal spinal alignment presented in this report is the result of many research projects on spinal alignment in normal subjects. [1-6] Normal values for all spinal angles and distances, utilized in this report, have been reported in the most prestigious journals in the Index Medicus literature. [1-6] Your abnormal spinal displacements (subluxations) will be compared to these normals.

These measurements of spinal displacements, utilized here, are mathematical utilizing geometric methods. This geometric line drawing analysis has been shown to be very reliable (repeatable) and valid (accurate). [7-11]

Clinical Impression/Diagnosis

A Clinical Impression (Diagnosis) of your condition is derived from a variety of sources, including the consultation and discussion of your health history with your doctor, any orthopedic and/or neurological examinations, range of motion examination, postural examination, and the radiographic examination.

For recordkeeping purposes, the Clinical Impression is reduced to numerical codes, which have been agreed upon world wide. These International Classification of Diseases codes are termed "ICD" codes, are given to healthcare providers in code books, and are lists of specific agreed upon numbers followed by brief descriptions. These numbered ICD codes make for easy communication of your health problems, when given to any third party payers or state government entities, i.e., insurance companies, Workers Compensation, lawyers, courts, State Boards, etc.

Generally, a patient can trace his/her present condition back to a past injury, which is termed mode of onset. Using ICD codes, your doctor has reduced your condition to 5 different categories: (1) mode of onset of condition (accidents, falls, etc), (2) global postural displacements, (3) regional and/or segmental spinal displacements, (4) unchangeable complicating factors (ligament damage, spinal fractures, osteoarthritis, etc), and (5) disease syndromes (headaches, neck pain, arm pain, mid back pain, low back pain, leg pain, sciatica, etc.).

X-RAY Report of Findings

Side View of Your Neck (Lateral Cervical View)

The normal healthy curvature of a neck from the side.

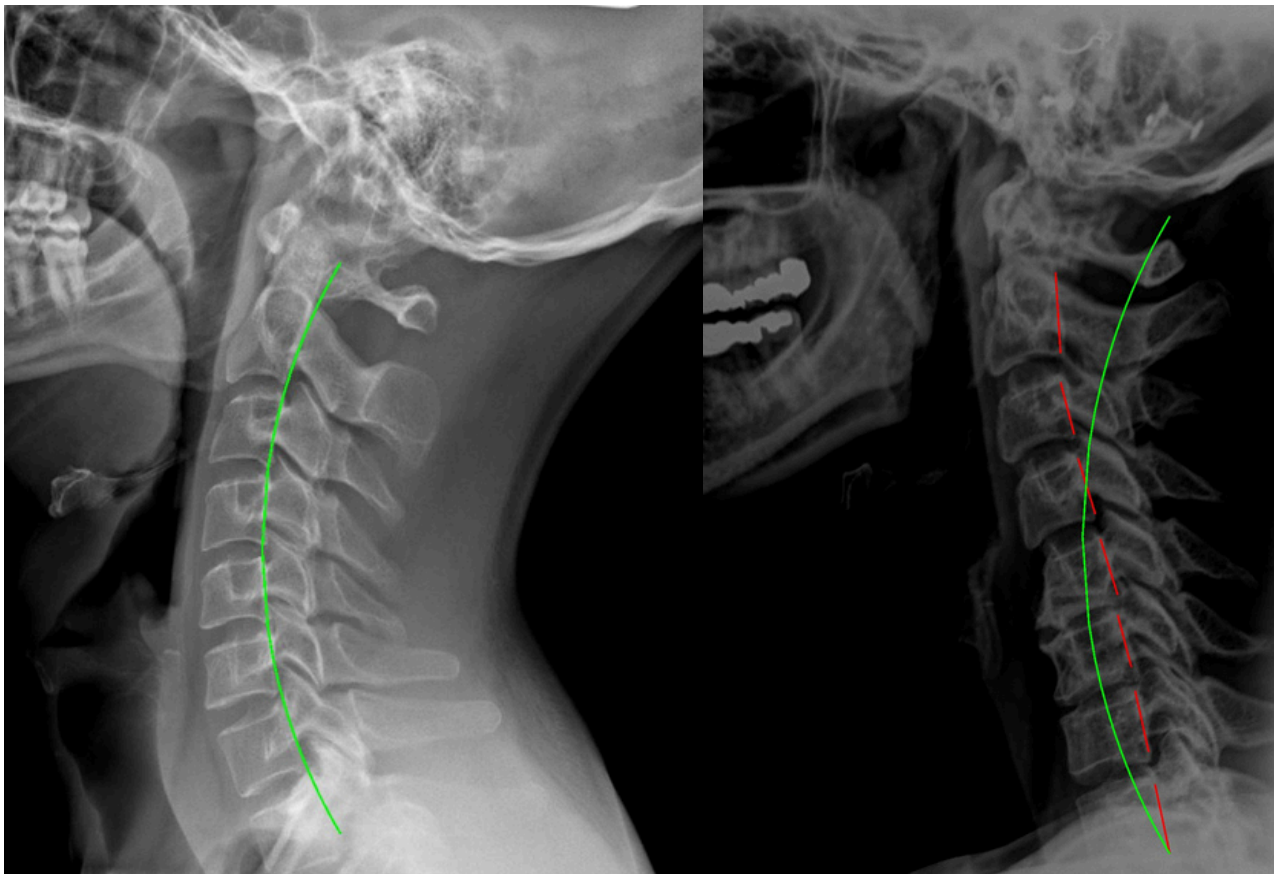
The green curved line represents the normal, healthy position for your neck.

No spinal arthritis is apparent and healthy disc spaces are visualized.

Your neck position from the side.

This green line represents the normal, healthy position for your neck.

This red line represents where your neck is currently positioned.



Front

BackFront

Back

Notes about your condition:

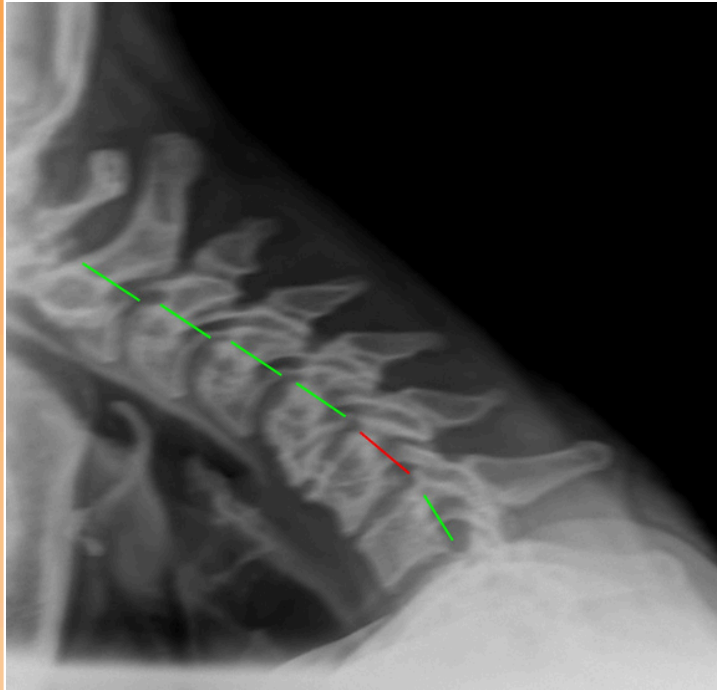Your head is positioned 23.9 mm forward. Your neck curve measures -9.2° and should be -42.0° (a negative sign indicates lordosis or normal curve direction). This represents a 78.1% loss in your curve compared to the normal neck curve.

X-RAY Report of Findings

Side View of Your Neck Flexed and Extended (Lateral Cervical Flexion and Extension View)

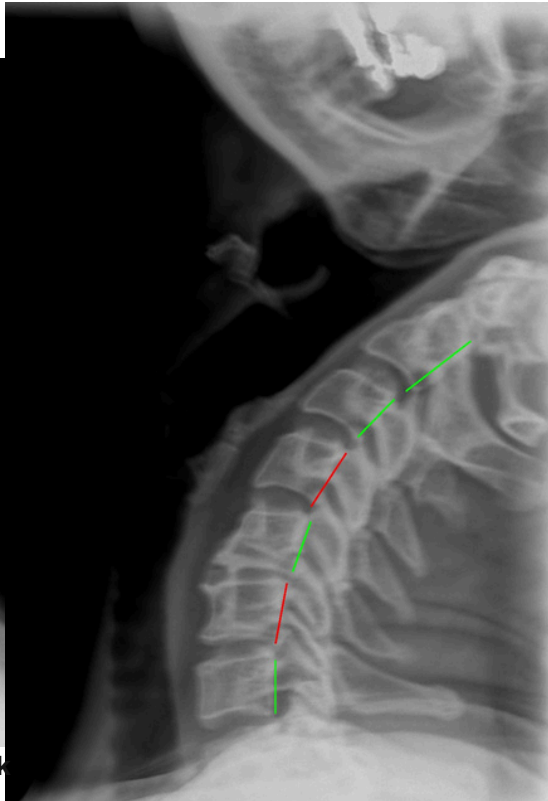
This line represents where your neck is currently positioned with normal displacements.

This line represents where your neck is currently positioned with abnormal displacements.



Front

Back



Front

Back

Notes about your condition:

This x-ray is taken to observe the stability of your spinal ligaments when you bend your head forward and backwards. Ideally there should be minimal shifting of one vertebrae relative to the adjacent vertebrae. When spines are injured, it is common to see an abnormal increase in displacement slippage forward or backwards and/or an increase in angulation between In your spine when you tip your head down (flexion position), you show possible damage at the C6-C7 spinal levels.

In the head backwards position (extension position), your spine demonstrates possible ligament damage at the C4-C5, C6-C7 spinal levels.

X-RAY Report of Findings

Front View of Your Neck (AP Cervical View)

The normal healthy position of the neck from the front.

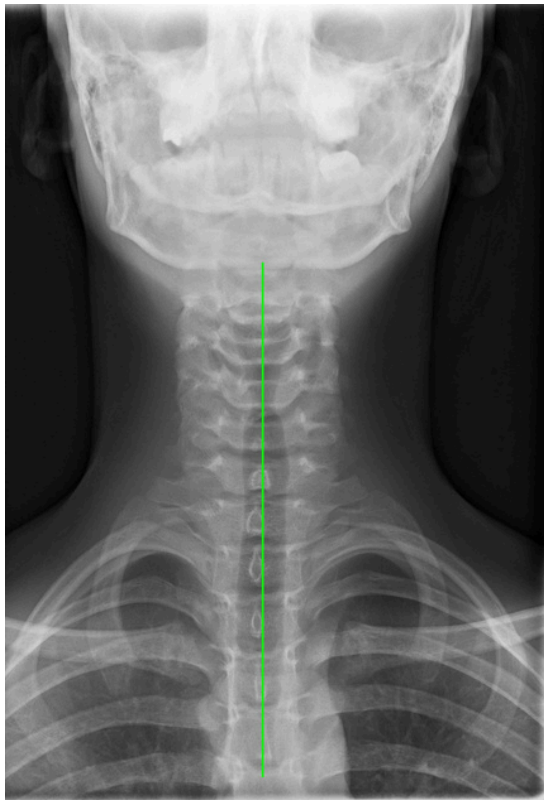
The green line represents the normal, healthy position for your neck.

No arthritis and healthy joint spaces are visualized.

Your neck position from the front.

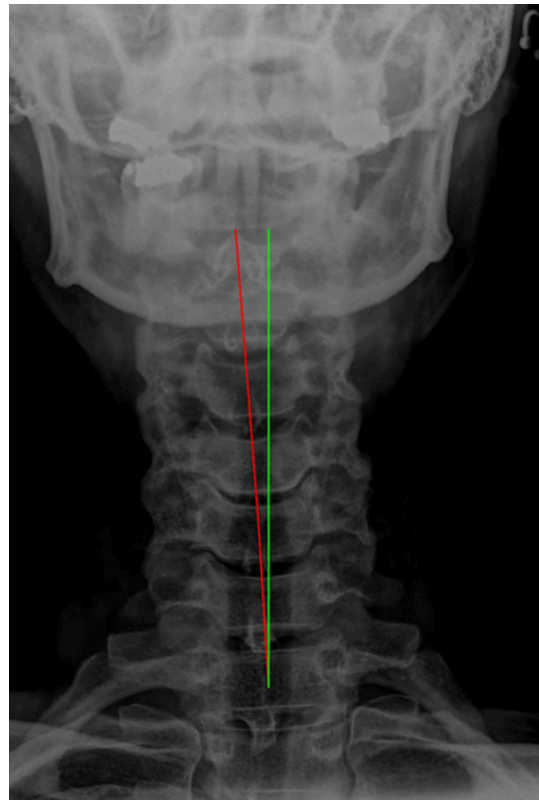
This green line represents the normal, healthy position for your neck.

This red line represents where your neck is currently positioned.



Right

Left



Right

Left

Notes about your condition:

Your head is shifted 8.3 mm to the right, you have a mid neck tilt angle of 0.9° to the right and a lower neck tilt of 3.4° to the right.

X-RAY Report of Findings

Side View of Your Mid Back (Lateral Thoracic Spine)

The normal healthy position of a mid back from the side.

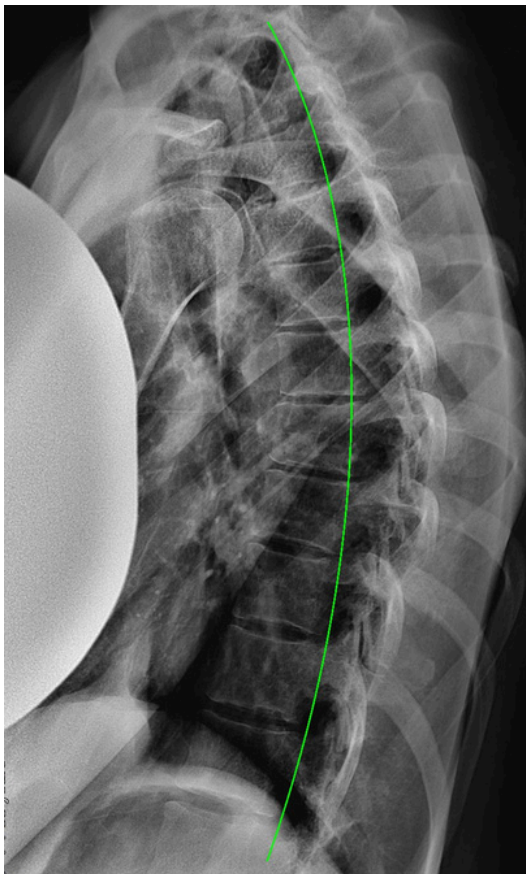
The green curved line represents the normal, healthy position for your ribcage.

No spinal arthritis is apparent and healthy disc spaces are visualized.

Your mid back position from the side.

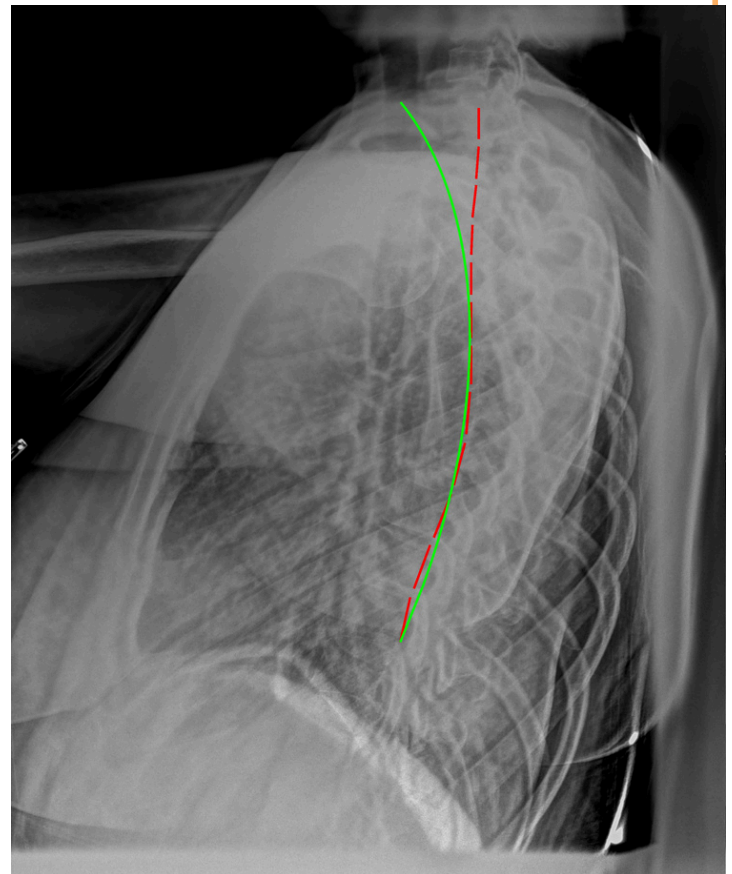
This green line represents the normal, healthy position for your mid back curve.

This red line represents where your mid back curve is currently positioned.



Front

Back



Front

Back

Notes about your condition:

Your spinal curve is positioned 38.5 mm backward. Your thoracic spine curve measures 12.5° and should be 44°. This represents a 71.5% loss in your curve compared to the normal thoracic spine curve.

X-RAY Report of Findings

Front View of Your Thoracic

The normal healthy position of a mid back from the front.

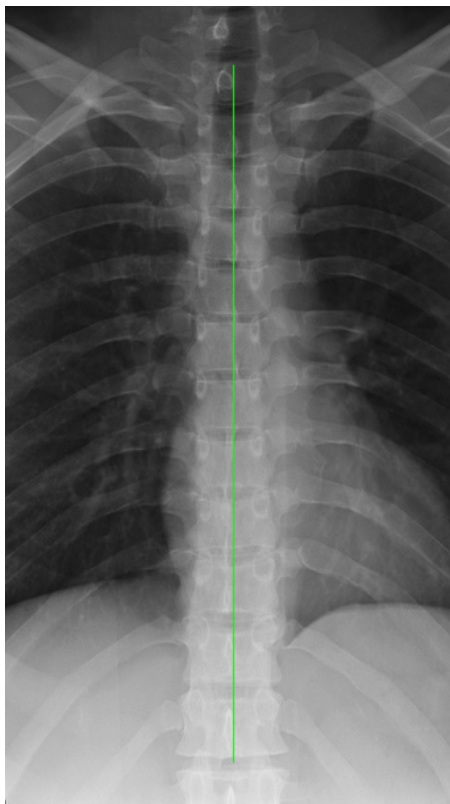
The green line represents the normal, healthy position for your ribcage.

No arthritis and healthy joint spaces are visualized.

Your mid back position from the front.

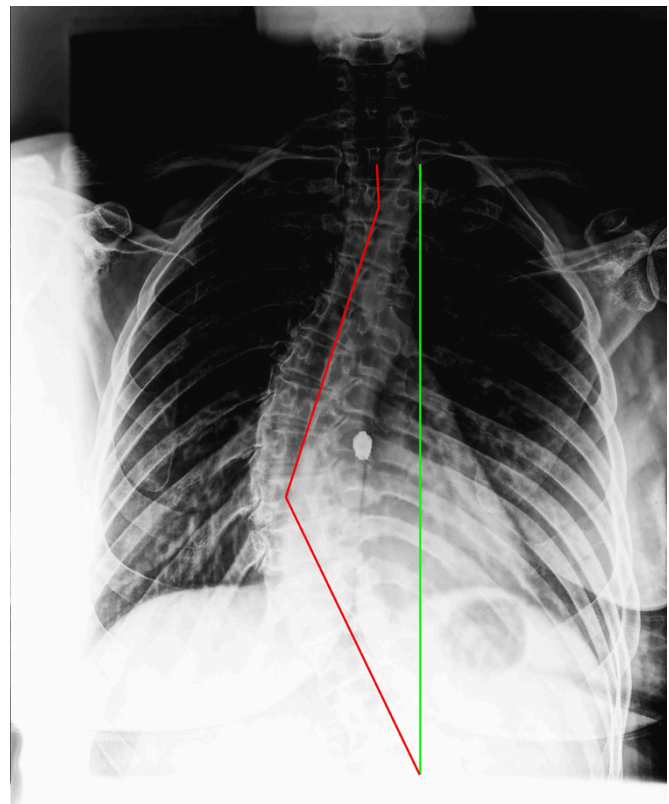
This green line represents the normal, healthy position for your Thoracic spine.

This red line represents where your Thoracic spine is positioned.



Right

Left



Right

Left

Notes about your condition:

Your thoracic x-ray demonstrated that you have a scoliosis that consists of one major curvature. Your curve measured from vertebra T2 to vertebra L2 measured 15.4° (mild) using the "Cobb" method analysis and measured 43.4° (extreme) using the "Risser-Ferguson" method of analysis. These methods of analysis are what spine doctors use to measure the severity of a scoliosis.

X-RAY Report of Findings

Side View of Your Low Back (Lateral Lumbar View)

The normal healthy curvature of a low back from the side.

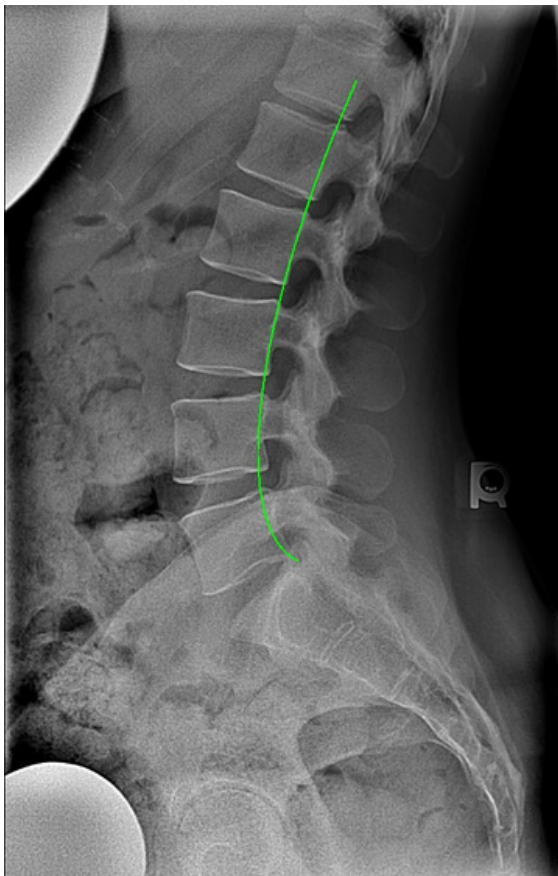The green curved line represents the normal, healthy position for low back curve.

No spinal arthritis is apparent and healthy disc spaces are visualized.

Your low back position from the side.

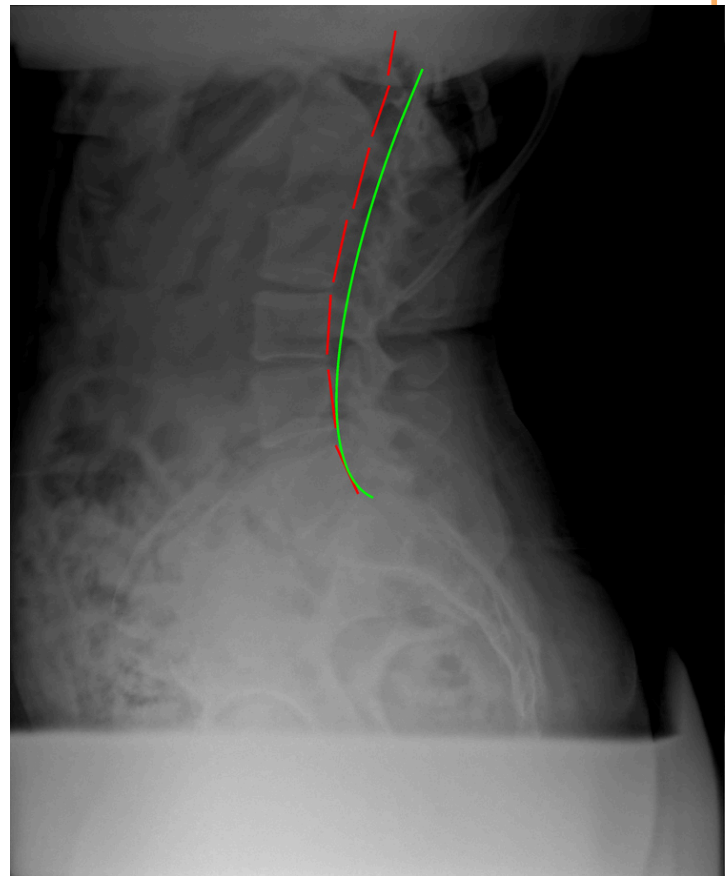
This green line represents the normal, healthy position for your low back curve.

This red line represents where your low back curve is currently positioned.



Front

Back



Front

Back

Notes about your condition:

Your rib cage is positioned 15.9 mm forward relative to your pelvis. Your low back curve measures -26.1° and should be -40° (a negative sign indicates lordosis or normal curve direction). This represents a 34.7% loss in your curve compared to the normal low back curve.

X-RAY Report of Findings

Front View of Your Low Back (AP Lumbar View)

The normal healthy position of a low back from the front.

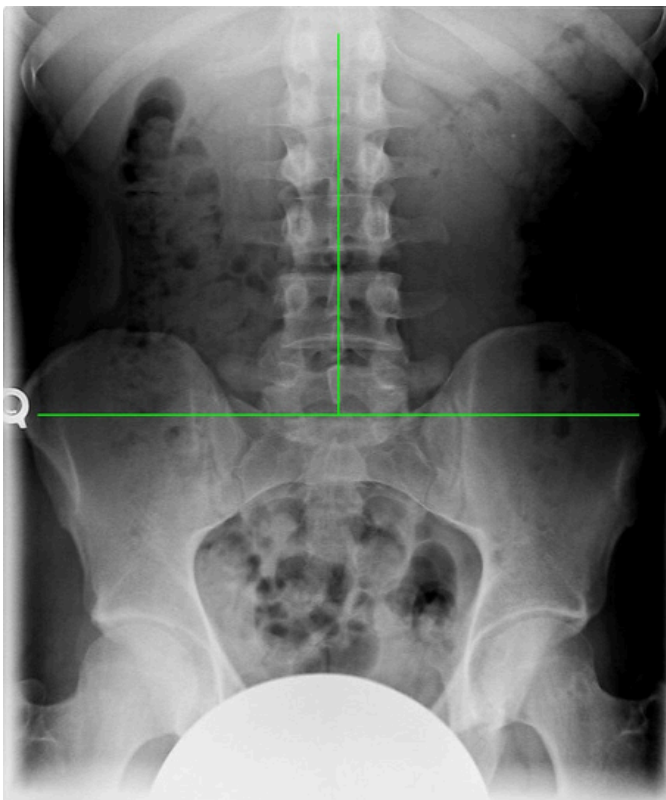
The green line represents the normal, healthy position for your low back.

No arthritis and healthy joint spaces are visualized.

Your low back position from the front.

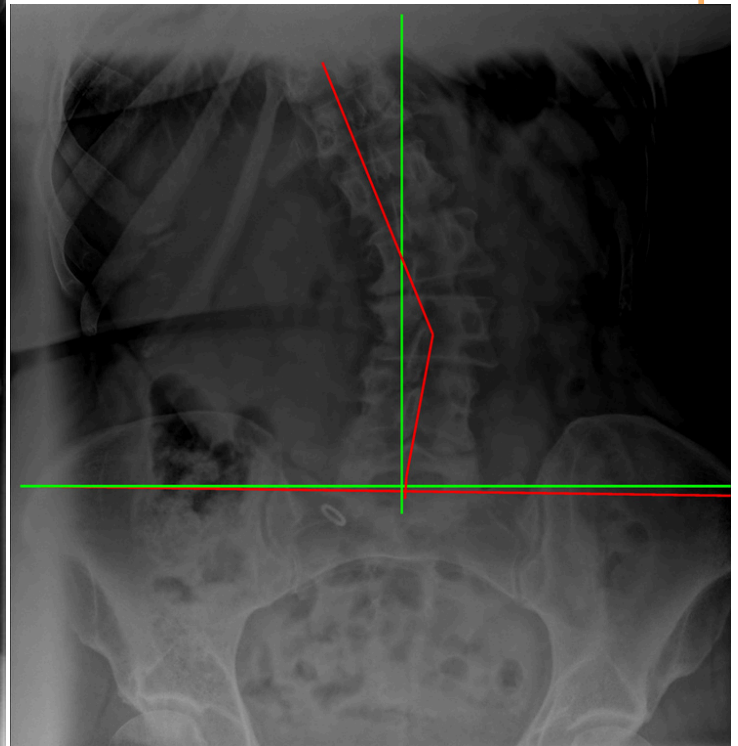
This green line represents the normal, healthy position for your low back.

This red line represents where your low back is currently positioned.



Right

Left



Right

Left

Notes about your condition:

Your lumbar x-ray demonstrated that you have a scoliosis that consists of one major curvature. Your curve measured from vertebra T12 to vertebra L6 measured 24.6° (moderate) using the "Cobb" method analysis and measured 32.7° (severe) using the "Risser-Ferguson" method of analysis. These methods of analysis are what spine doctors use to measure the severity of a scoliosis.

X-RAY Report of Findings

Side View of Your Full Spine

The normal healthy curvature of a Full Spine from the side.

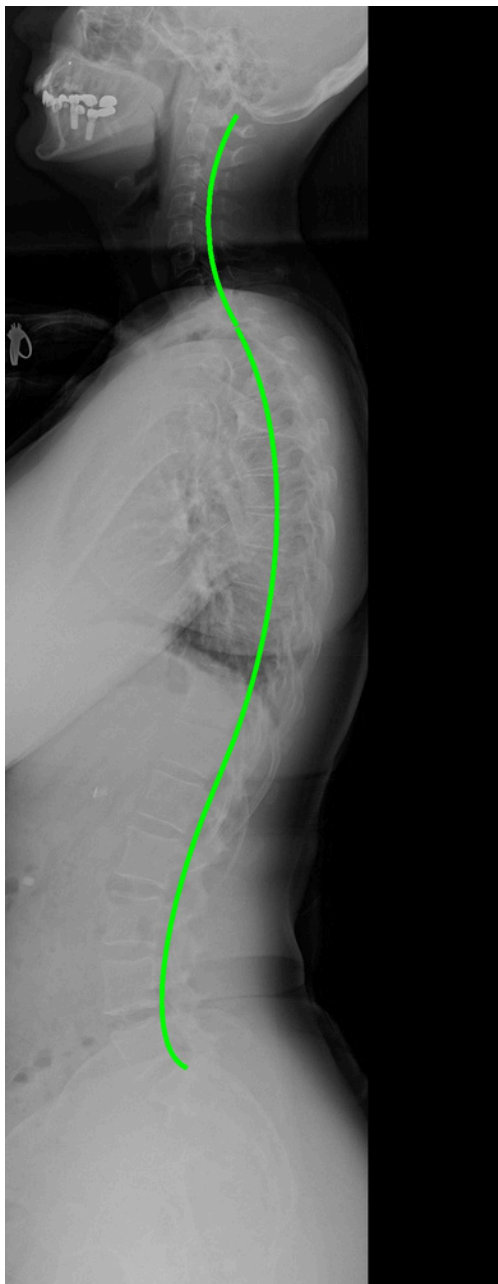
The green curved line represents the normal, healthy position for your Spine.

There are 3 opposing spinal curves in the neck, ribcage, low back.

Your Full Spine position from the side.

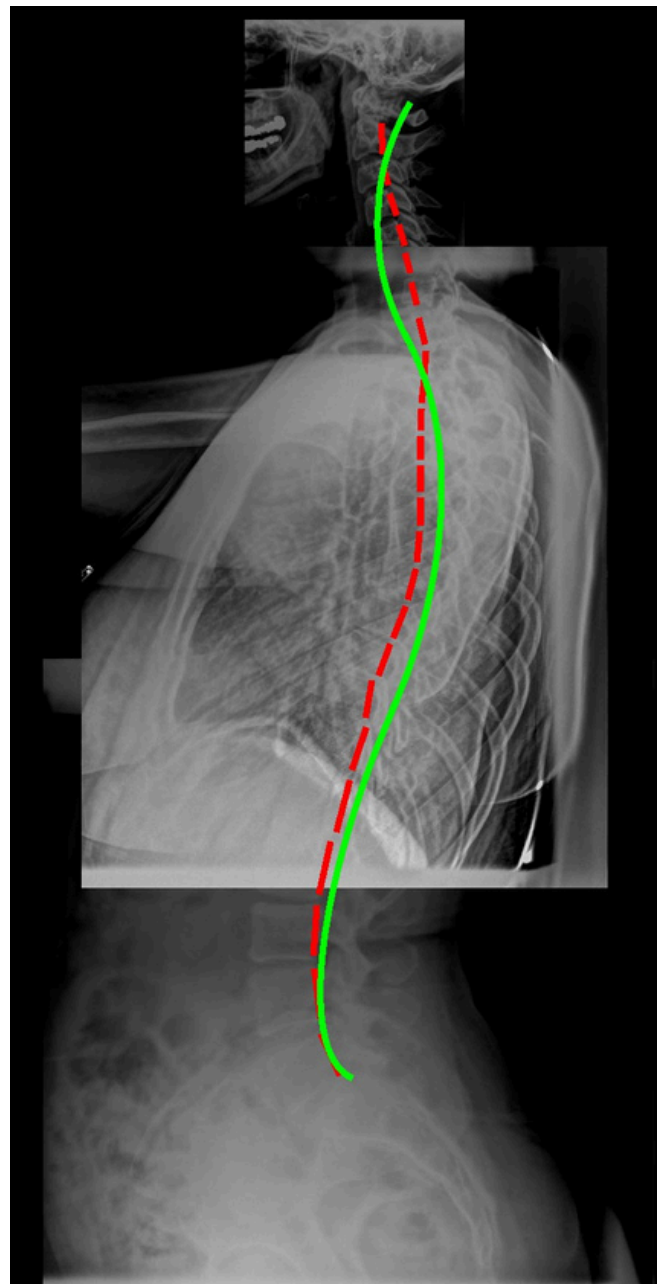
This green line represents the normal, healthy position for your full spine curve.

This red line represents where your full spine curve is currently positioned.



Front

Back



Front

Back



X-RAY Report of Findings

Side View of Your Full Spine

Notes about your fullspine condition:

Your neck curve measures -9.2° and should be -42.0° (a negative sign indicates lordosis or normal curve direction). This represents a 78.1% loss in your curve compared to the normal neck curve.

Your thoracic spine curve measures 12.5° and should be 44.0° . This represents a 71.5% loss in your curve compared to the normal thoracic spine curve.

Your low back curve measures 26.1° and should be -40.0° (a negative sign indicates lordosis or normal curve direction). This represents a 34.7% L in your curve compared to the normal low back curve.

Your neck is positioned 23.9mm forward of your torso. Your upper back/torso is positioned 38.5mm backward compared to your lower torso. Your lower torso is positioned 15.9mm forward of your pelvis/hips. Your total percent change considering your neck, your mid-back and your low back is 184.3% from normal. The balance point of your neck relative to your pelvis is 5.1mm backward.

X-RAY Report of Findings

Front View of Your Fullspine

The normal healthy position of a spine from the front.

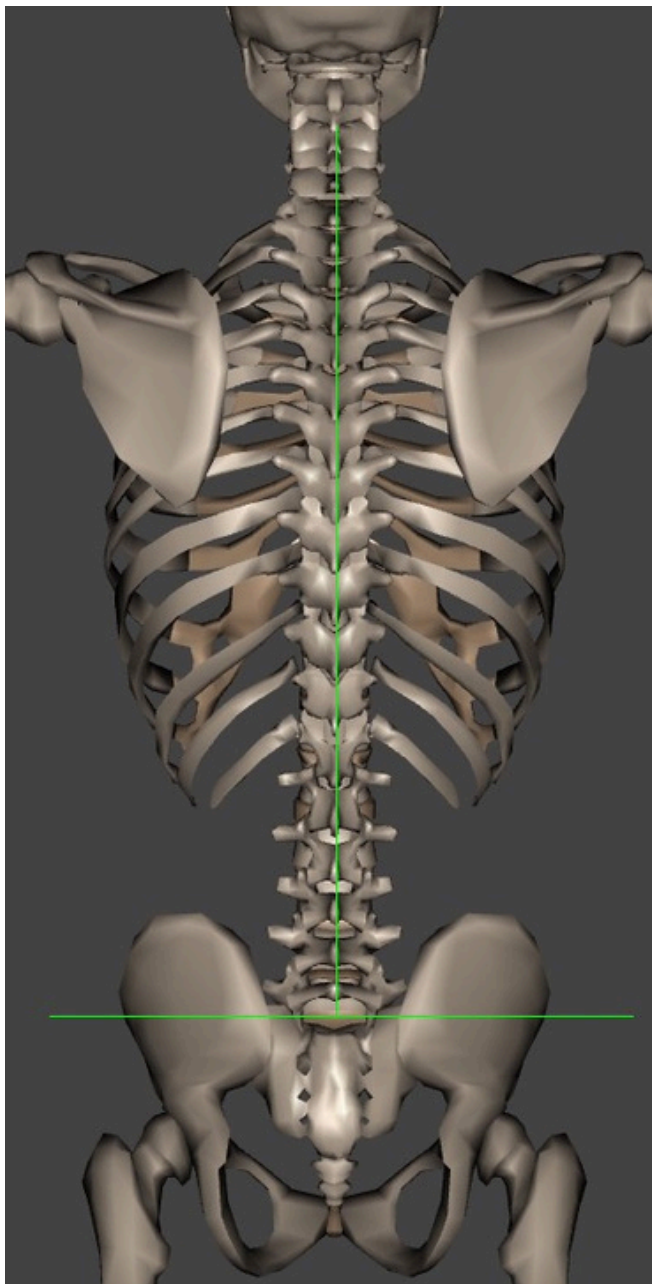
The green line represents the normal, healthy position for your spine.

No arthritis and healthy joint spaces are visualized.

Your fullspine position from the front.

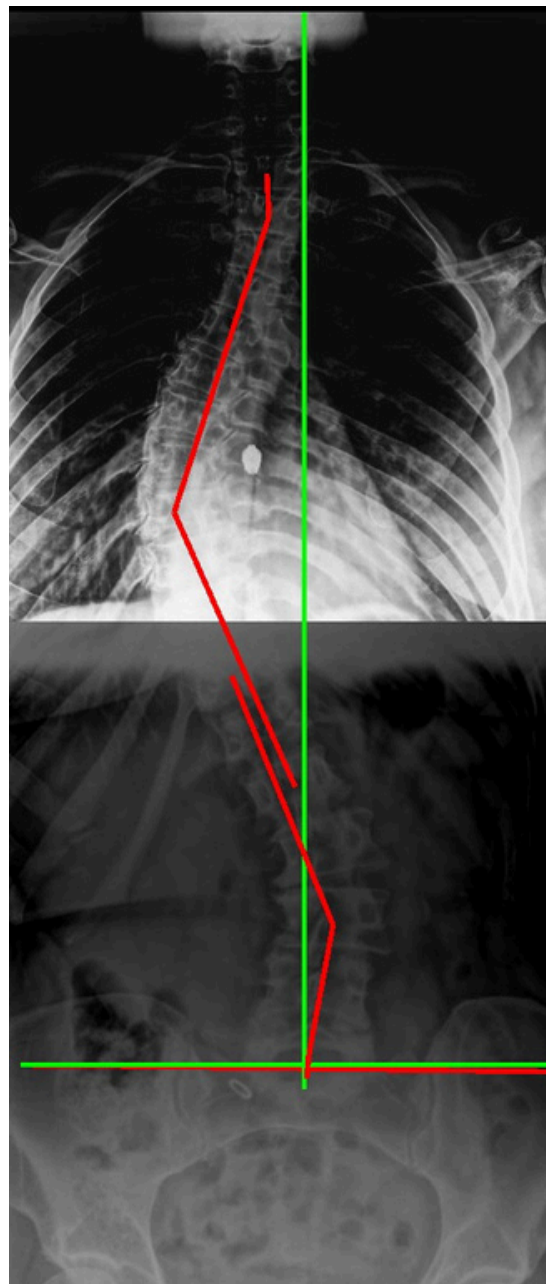
This green line represents the normal, healthy position for your spine.

This red line represents where your spine is positioned.



Right

Left Right



Left



X-RAY Report of Findings

Front View of Your Fullspine

Notes about your condition:

Your x-ray demonstrated that you have a scoliosis that consists of two major curvatures.

Your curve measured from vertebra T2 to vertebra L2 measured 23.2° (moderate) using the “Cobb” method analysis and measured 41.5° (extreme) using the “Risser-Ferguson” method of analysis.

Your curve measured from vertebra T12 to vertebra L6 measured 29.4° (moderate) using the “Cobb” method analysis and measured 32.7° (severe) using the “Risser-Ferguson” method of analysis. These methods of analysis are what spine doctors use to measure the severity of a scoliosis.